

# SERIES #4

Let's gain

---

# MOGmentum

a collaborative series brought to you by The Sumaira Foundation and The MOG Project



# WHAT SYMPTOMS ARE ASSOCIATED WITH MOG ANTIBODY DISEASE?

Well, that's a complicated question!

It depends on which part of the central nervous system is being affected. Generally, the areas affected in MOG Antibody Disease (MOG-AD) include the following:

BRAIN

OPTIC NERVE

SPINAL CORD

Inflammation caused by MOG-AD in these areas causes the following:

BRAIN  
↓  
Encephalitis

OPTIC NERVE  
↓  
Optic Neuritis

SPINAL CORD  
↓  
Transverse Myelitis

Encephalitis, optic neuritis, or transverse myelitis may occur on their own, together at the same time, or on separate occasions (for example someone may initially have only optic neuritis and then develop month to years later transverse myelitis).

When there is inflammation in the brain and spinal cord occurring at the same time (+/- the optic nerve) this is called **encephalomyelitis**. This kind of presentation is more common in children with MOG-AD, whereas adults more commonly present with optic neuritis and/or transverse myelitis.



# WHAT PARTS OF THE BRAIN ARE ASSOCIATED WITH SOME OF THE SYMPTOMS I FEEL?

## Cerebrum

- Disorientation / Confusion / Altered consciousness (e.g., confusion, stupor, lethargy, and coma)
- Visual changes
- Seizures (symptoms vary and can include a sudden change in awareness or full loss of consciousness, unusual sensations or thoughts, involuntary twitching or stiffness in the body or severe stiffening and limb shaking)
- Inability or difficulty communicating (verbal and/or written)
- Difficulty with movement
- Inability to think clearly, concentrate and remember new information (cognitive dysfunction)
- Psychiatric symptoms (e.g. anxiety, apathy, irritability, hallucinations, hyperactivity, aggressive behavior, mood changes)
- Weakness, muscle spasms, stiffness
- Numbness and other changes in sensation in the body



## Cerebellum

- Lack of coordination
- Slurred speech
- Trouble eating and swallowing
- Difficulty walking
- Eye movement abnormalities
- Tremors
- Jumping vision (oscillopsia)

## Brainstem

- Motor and sensory disturbances.
- Nausea, vomiting and/or hiccups.
- Double vision (diplopia)
- Jumping vision (oscillopsia)
- Facial numbness and/or pain (including burning/electrical sensation, pins/needles, sensitivity to touch)
- Altered taste (dysgeusia)
- Ringing or buzzing in the ears (tinnitus)
- Decreased hearing
- A spinning or movement sensation (vertigo)
- Imbalance, walking difficulty
- Difficulty in swallowing foods or liquids (dysphagia)
- Slurred speech (dysarthria)
- Difficulty breathing

- Symptoms may or may not be MOG-related. Only your medical provider can determine the root cause.
- Symptoms listed here were gathered from clinical studies mentioned in the reference section. As MOG-AD research evolves, new symptoms may be identified.



# IF DIAGNOSED WITH OPTIC NEURITIS (ON), A PERSON COULD EXPERIENCE...

- Blurred vision
- Complete loss of vision
- Impaired color vision
- Sensitivity to light (photophobia)
- Partial loss of vision or blind spot (scotomas and other visual field defects)
- Pain around or behind the eye, usually worse with movement

One attack (monophasic)  
Multiple attacks (multiphasic)



- Symptoms may or may not be MOG related. Only your medical provider can determine the root cause.
- Symptoms listed here were gathered from clinical studies mentioned in the reference section. As MOG-AD research evolves, new symptoms may be identified.



# IF DIAGNOSED WITH TRANSVERSE MYELITIS (TM), A PERSON COULD EXPERIENCE...

## Sensory issues

- Pins and needles, tingling, electrical sensation, numbness, and/or burning/cold sensations (paresthesias)
- Sensitivity to touch
- Pain radiating from your back and hip into your legs through the spine (radicular pain)
- An electrical shock sensation that occurs on bending the neck and shoots down the spine (Lhermitte's phenomenon)
- Band-like abdominal or chest pressure

One attack (monophasic)  
Multiple attacks (multiphasic)



## Motor/Functional issues

- Limb weakness (can be both sides or just one side)
- Muscle stiffening or tightening; twitching (limb spasticity)
- Painful involuntary muscular contractions (painful tonic spasms)
- Bowel issues (constipation, incontinence or urgency)
- Bladder issues (urgency and/or frequency, difficulty emptying, incontinence)
- Difficulty breathing (dyspnea)

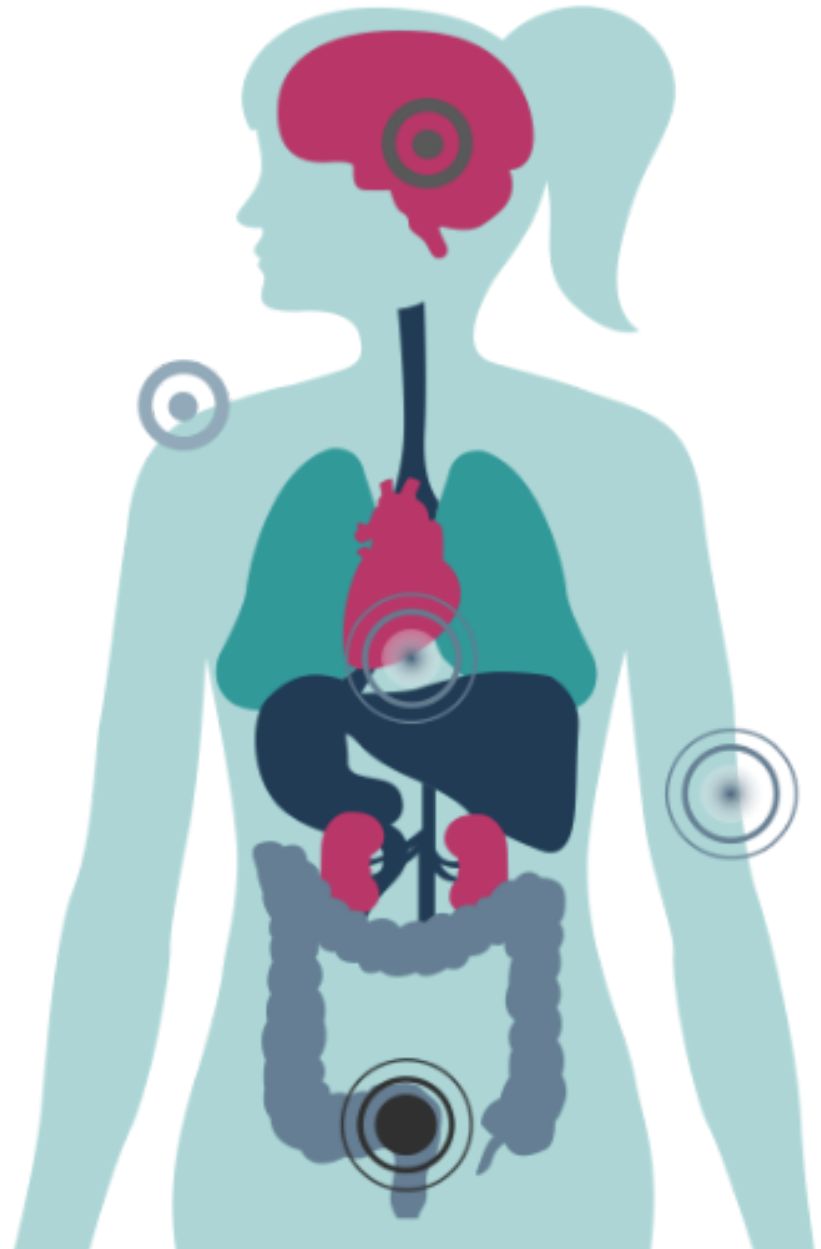
- Symptoms may or may not be MOG related. Only your medical provider can determine the root cause.
- Symptoms listed here were gathered from clinical studies mentioned in the reference section. As MOG-AD research evolves, new symptoms may be identified.



# OTHER GENERAL SYMPTOMS THAT CAN OCCUR IN MOG-AD INCLUDE...

## General Issues

- Headache
- Neck stiffness
- Fever
- Fatigue
- Dizziness
- Sensitivity to heat, exercise and/or stress (Uhthoff's phenomenon)
- Irritability
- Anxiety
- Loss of appetite



- Symptoms may or may not be MOG related. Only your medical provider can determine the root cause.
- Symptoms listed here were gathered from clinical studies mentioned in the reference section. As MOG-AD research evolves, new symptoms may be identified.



# Wow, that's complicated!

## How does my doctor diagnose what type I have?

Fortunately, your doctor not only has enough experience and training to diagnose which disorder you have but also has several tools in the toolbox to choose from, including:

- **Considering your most common and most prominent symptoms**
- **Your MRI, OCT, and other diagnostic scans**
- **Your lab work:**
  - Including AQP4 and MOG antibodies
  - Spinal fluid analysis (not always necessary)
  - Other bloodwork which will vary depending on the clinical picture
- **Your short-term and long-term responses to therapy**
  - Symptoms you present with if you relapse
  - Changes in your scans or lab work



# What do my MOG Antibody titer levels tell my doctor?

- At this point, the test results mainly just tell your doctor that your problem is caused by MOG-AD and it helps aid in your diagnosis and treatment plan.
- MOG antibody titer levels generally are higher during a relapse than while in remission; however, patients may experience relapses with stable titer levels or titer level decreases.
- Even in some cases, patients have relapsed at a low or negative titer level.
- A proportion of patients have shown decreasing titer levels or a negative titer level within 8 to 36 months after their initial attack; this may be associated with a monophasic disease course.
- However, following negative results, some patients can return to having blood test results with a positive titer level.
- Due to the possibility of fluctuation in titers and the disappearance of titers in some patients, some specialists have recommended re-test intervals every 6-12 months, but the clinical utility of monitoring titers is not clear.





# What is a relapse vs pseudo-relapse?

- A **relapse** is objectively defined in a medical setting when you present to your doctor or hospital with new or worsening central nervous system symptoms. Generally, if your symptoms gradually worsen over 24-48 hours, there is heightened concern of a relapse.
  - The presence of new inflammation or lesions on MRI confirm a relapse, however, lack of MRI findings does not rule out a relapse. This is where your doctor will need to decide using medical expertise.
  - For example, for most MOG-AD patients who experience ON, the earliest indicator of a true relapse vs pseudo-relapse is vision loss.
  - Often called a **flare** by the MOG-AD Community
- A **pseudo-relapse** is the recurrence of neurologic symptoms often due to an exacerbating factor or trigger, such as heat, stress, or sickness. Pseudo-relapses can often be distinguished clinically from relapses by their fluctuance in severity and improvement over 24-48 hours.
  - Pseudo-relapses will never show any new or worsening lesions on MRI.



# What should I look for when deciding to call my doctor?

- **New or worsening symptoms from your baseline that last more than 24 hours**
  - Your baseline is where you were from a daily symptom perspective prior to the change.
    - For example: if you're used to seeing a particular item clearly, and suddenly you can't, you may be experiencing a relapse.
  - Distinguishing new or worsening symptoms is crucial to determining whether you are having a relapse.
  - Only you and your doctor are familiar with your baseline since,
    - It may take months after an attack to recover, and full recovery is not guaranteed.
    - Some symptoms may be permanent and need medications to alleviate.
- **Understanding what your body is trying to tell you may take some practice.**
  - There are many MOG-AD community members available for support and advice.
  - In time, you will understand your pattern of symptoms.



**The MOG Progression Map** will help you understand where you might go in terms of symptoms based on the initial symptoms that you have had in the past.

**[<https://mogproject.org/resources/mogmentum/mogmentum-series-2/>]**

- Seasoned/experienced MOG-AD patients/caregivers may be able to know right away.



# What do doctors hear from patients?

## Optic Nerve

Is it dark in here?

I see grey smudges.

Everything is blurry.

Everything looks more pale and pixelated.

It's like a knife is piercing my head near my eyes.

I can't see anything!  
It's completely dark!

Colors don't look as bright.

My eyes hurt when I look around.

It's like I am in a smoky room.



# What do doctors hear from patients?

## Brain & Brainstem

She's not making sense.

There is so much pressure with this headache.

I just can't seem to focus.

I stumble and lose my balances.

Her tantrums come out of nowhere. She is always angry.

The seizures are getting worse.

I am so tired. I can't get through the day without a nap.

I have MOG FOG! I can't remember anything.

I am losing my hearing!

He is unable to answer me when I ask him a question.

I'm so nauseous I can't eat.

I can't muster any strength to move.



# What do doctors hear from patients?

## Spinal Cord

I am afraid I will have an accident. I can't leave the house.

I have pain in my back.

I am feeling a stinging sensation.

There is a burning pain in my body.

I have bruises from the spasms.

Suddenly her gait just looked really strange.

My belly hurts. I haven't gone in days.

The pain in my chest is terrible.

I have such bad leg pain.

My legs are weak.

It feels like my ribs are being squeezed



**Let's help you communicate your situation a little better with your doctor...**  
 Categorizing the gravity of your situation into **Green**, **Yellow** and **Red** Level of Concern is an easy way to determine how you and your doctor should react:

LEVEL OF CONCERN	Is this a new symptom?	How bad is this symptom in comparison with your baseline?	How many hours has this been going on?	Do you have body stressors (e.g., extreme heat)?	Are you currently experiencing, or have you recently experienced infection/illness or are you just not feeling well?
<b>Green (Low)</b> Likely a pseudo-relapse	<b>NO</b>	Noticeable, but not as bad as during past relapses or initial attack	Less than 24 hours	<b>YES</b>	<b>YES or NO</b>
<b>Yellow (Medium)</b> Possibly a new relapse	<b>YES or NO</b>	Mild and causing a mild lack of function	More than 24 hours	<b>NO</b>	<b>YES</b>
<b>Red (High)</b> Very worrisome that a new relapse is occurring	<b>YES</b>	More severe and a causing a lack of function	More than 24 hours and not improving	<b>NO</b>	<b>YES</b>

\*When identifying a Level of Concern, if all criteria are not met for a particular level, please err on the side of caution and choose the highest level where criteria are met\*

# I SUSPECT THAT I AM HAVING A RELAPSE!

## WHAT SHOULD I DO?

- MOG-AD relapses may come on quickly. It is up to you to avoid new and permanent damage by addressing the issue quickly.
- Call your doctor
  - If you are unable to get in touch with your doctor, we strongly suggest you consider going to the ER or A&E.
- There are several ways to verify that you are having a relapse, so your doctor may recommend one or more of these tests, after performing a physical examination, depending on your symptoms:
  - MRI
  - Blood tests
  - Lumbar puncture (spinal tap)
  - Dilated ophthalmologic examination
  - Optical Coherence Tomography (OCT)
  - Visual Field Testing
  - Other physical examinations and cognitive tests



# LET'S GET PREPARED!

- **Being prepared for your next attack is the best way to live with confidence and know what to do when you might not necessarily be able to think quickly.**
  - Getting family members or caretakers involved in this planning is crucial because you might not be able to execute your plan without help

## WE SUGGEST...

- **Creating an Action Plan with your doctor's help, which is only for you, your caretaker and your doctor and is an agreement on how a relapse will be handled.**
  - This type of plan would be based on the Green/Yellow/Red Level of Concern Table and, for each of these levels include:
    - How you interact with your doctor including the best contact method.
    - What the process will be once the plan is put into motion.
    - A time period in which you can expect the doctor to respond.
    - At which level of concern, the ER (A&E) will fit into this plan and how you and your doctor will interact with these medical providers.
- **Creating an ER/A&E Plan to take to an Emergency Room (ER) or Accident and Emergency (A&E) facility**
  - It will be important to provide emergency services with an outline of treatment approaches that have worked for you in the past which would be laid out by your doctor in case he/she cannot be reached.
  - You would want to include your past medical records, any medications you are on, any relevant tests (e.g. MOG titer tests), and any allergies.
  - Your treating medical doctor's contact information.
- **Tracking your relapses which can come in handy in discussions with any medical provider concerning your condition.**
  - These documents can be made available on hand-held devices such as your smartphone or tablet.
  - For those who do not have these devices, a binder should be ready to take with you.

**MOG-AD ACTION PLAN, MOG-AD EMERGENCY PLAN, AND OUR MOG-AD RELAPSE TRACKER**



[HTTPS://MOGPROJECT.ORG/RESOURCES/MOGMENTUM/MOGMENTUM-SERIES-4](https://mogproject.org/resources/mogmentum/mogmentum-series-4)



# WHAT'S THE TAKEAWAY?

- Get to know your body, keep track of exactly what you experience with your relapses
- You may even want to keep a symptom diary until you better understand your symptom pattern
- Learn about the potential symptoms of MOG-AD (yes, we know it's a lot, but you can do it!)
- Keep communication open with your medical providers and let them know how important coordinated fast action is to your well-being.
  - Remember, you and your doctor are a team!
- Join our support network, or those of our partners; share with others, and learn what can happen with your symptoms based on other's experiences – there is strength in numbers!



- Lana-Peixoto MA, Talim N. Neuromyelitis Optica Spectrum Disorder and Anti-MOG Syndromes. *Biomedicines*. 2019 Jun 12;7(2):42. doi: 10.3390/biomedicines7020042. PMID: 31212763; PMCID: PMC6631227.
- Hacohen Y, Banwell B. Treatment Approaches for MOG-Ab-Associated Demyelination in Children. *Curr Treat Options Neurol*. 2019 Jan 22;21(1):2. doi: 10.1007/s11940-019-0541-x. PMID: 30671648; PMCID: PMC6342853.
- Ramanathan S, Mohammad S, Tantsis E on behalf of the Australasian and New Zealand MOG Study Group, et al Clinical course, therapeutic responses and outcomes in relapsing MOG antibody-associated demyelination *Journal of Neurology, Neurosurgery & Psychiatry* 2018;89:127-137.
- Ramanathan S, Dale RC, Brilot F. Anti-MOG antibody: The history, clinical phenotype, and pathogenicity of a serum biomarker for demyelination. *Autoimmun Rev*. 2016 Apr;15(4):307-24. doi: 10.1016/j.autrev.2015.12.004. Epub 2015 Dec 17. PMID: 26708342.
- Jarius, S., Paul, F., Aktas, O. et al. MOG encephalomyelitis: international recommendations on diagnosis and antibody testing. *J Neuroinflammation* 15, 134 (2018). <https://doi.org/10.1186/s12974-018-1144-2>
- Jurynczyk M, Messina S, Woodhall MR, Raza N, Everett R, Roca-Fernandez A, Tackley G, Hamid S, Sheard A, Reynolds G, Chandratre S, Hemingway C, Jacob A, Vincent A, Leite MI, Waters P, Palace J. Clinical presentation and prognosis in MOG-antibody disease: a UK study. *Brain*. 2017 Dec 1;140(12):3128-3138. doi: 10.1093/brain/awx276. Erratum in: *Brain*. 2018 Apr 1;141(4):e31. PMID: 29136091.
- Ramanathan S, Mohammad S, Tantsis E on behalf of the Australasian and New Zealand MOG Study Group, et al Clinical course, therapeutic responses and outcomes in relapsing MOG antibody-associated demyelination *Journal of Neurology, Neurosurgery & Psychiatry* 2018;89:127-137.
- Hennes EM, Baumann M, Schanda K, Anlar B, Bajer-Kornek B, Blaschek A, Brantner-Inthaler S, Diepold K, Eisenkölbl A, Gotwald T, Kuchukhidze G, Gruber-Sedlmayr U, Häusler M, Höftberger R, Karenfort M, Klein A, Koch J, Kraus V, Lechner C, Leiz S, Leyboldt F, Mader S, Marquard K, Poggenburg I, Pohl D, Pritsch M, Raucherzauner M, Schimmel M, Thiels C, Tibussek D, Vieker S, Zeches C, Berger T, Reindl M, Rostásy K; BIOMARKER Study Group. Prognostic relevance of MOG antibodies in children with an acquired demyelinating syndrome. *Neurology*. 2017 Aug 29;89(9):900-908. doi: 10.1212/WNL.0000000000004312. Epub 2017 Aug 2. PMID: 28768844.
- Reindl, Markus, et al. "International Multicenter Examination of MOG Antibody Assays." *Neurology - Neuroimmunology Neuroinflammation*, vol. 7, no. 2, 2020, doi:10.1212/nxi.0000000000000674.
- Tea, F., Lopez, J.A., Ramanathan, S. et al. Characterization of the human myelin oligodendrocyte glycoprotein antibody response in demyelination. *acta neuropathol commun* 7, 145 (2019). <https://doi.org/10.1186/s40478-019-0786-3>
- Krupp LB, Tardieu M, Amato MP, et al. International Pediatric Multiple Sclerosis Study Group criteria for pediatric multiple sclerosis and immune-mediated central nervous system demyelinating disorders: revisions to the 2007 definitions. *Multiple Sclerosis Journal*. 2013;19(10):1261-1267. doi:10.1177/1352458513484547
- Wingerchuk DM, Banwell B, Bennett JL, Cabre P, Carroll W, Chitnis T, de Seze J, Fujihara K, Greenberg B, Jacob A, Jarius S, Lana-Peixoto M, Levy M, Simon JH, Tenenbaum S, Traboulsee AL, Waters P, Wellik KE, Weinshenker BG; International Panel for NMO Diagnosis. International consensus diagnostic criteria for neuromyelitis optica spectrum disorders. *Neurology*. 2015 Jul 14;85(2):177-89. doi: 10.1212/WNL.0000000000001729. Epub 2015 Jun 19. PMID: 26092914; PMCID: PMC4515040.
- Prabhu, M. M., & Agrawal, U. (2019). Intractable Vomiting and Hiccups: An Atypical Presentation of Neuromyelitis Optica. *Cureus*, 11(11), e6245. <https://doi.org/10.7759/cureus.6245>
- Enweluzo, C., & Yarra, P. (2013). Neuromyelitis optica: an often forgotten cause of intractable nausea and vomiting. *Case reports in gastroenterology*, 7(2), 281–286. <https://doi.org/10.1159/000354145>

- Hyun J-W, Kwon YN, Kim S-M, Lee HL, Jeong WK, Lee HJ, Kim BJ, Kim SW, Shin HY, Shin H-J, Oh S-Y, Huh S-Y, Kim W, Park MS, Oh J, Jang H, Park NY, Lee MY, Kim S-H and Kim HJ (2020) Value of Area Postrema Syndrome in Differentiating Adults With AQP4 vs. MOG Antibodies. *Front. Neurol.* 11:396. doi: 10.3389/fneur.2020.00396
- Pandit L. (2015). Neuromyelitis optica spectrum disorders: An update. *Annals of Indian Academy of Neurology*, 18(Suppl 1), S11–S15. <https://doi.org/10.4103/0972-2327.164816>
- Kim, H. J., Paul, F., Lana-Peixoto, M. A., Tenenbaum, S., Asgari, N., Palace, J., Klawiter, E. C., Sato, D. K., de Seze, J., Wuerfel, J., Banwell, B. L., Villoslada, P., Saiz, A., Fujihara, K., Kim, S. H., & Guthy-Jackson Charitable Foundation NMO International Clinical Consortium & Biorepository (2015). MRI characteristics of neuromyelitis optica spectrum disorder: an international update. *Neurology*, 84(11), 1165–1173. <https://doi.org/10.1212/WNL.0000000000001367>
- Liaqat Ali Chaudhry et al. Acute disseminated encephalomyelitis: a call to the clinicians for keeping this rare condition on clinical radar. *Pan African Medical Journal.* 2018;29:138. [doi: 10.11604/pamj.2018.29.138.13942]
- Lee YJ. Acute disseminated encephalomyelitis in children: differential diagnosis from multiple sclerosis on the basis of clinical course. *Korean J Pediatr.* 2011 Jun;54(6):234-40. doi: 10.3345/kjp.2011.54.6.234. Epub 2011 Jun 30. PMID: 21949517; PMCID: PMC3174358.
- Ramanathan S, Mohammad SS, Brilot F, Dale RC. Autoimmune encephalitis: recent updates and emerging challenges. *J Clin Neurosci.* 2014 May;21(5):722-30. doi: 10.1016/j.jocn.2013.07.017. Epub 2013 Sep 15. PMID: 24246947.
- Menge T, Kieseier BC, Nessler S, Hemmer B, Hartung HP, Stüve O. Acute disseminated encephalomyelitis: an acute hit against the brain. *Curr Opin Neurol.* 2007 Jun;20(3):247-54. doi: 10.1097/WCO.0b013e3280f31b45. PMID: 17495616.
- Baumann M, Sahin K, Lechner C, Hennes EM, Schanda K, Mader S, Karenfort M, Selch C, Häusler M, Eisenkölbl A, Salandin M, Gruber-Sedlmayr U, Blaschek A, Kraus V, Leiz S, Finsterwalder J, Gotwald T, Kuchukhidze G, Berger T, Reindl M, Rostásy K. Clinical and neuroradiological differences of paediatric acute disseminating encephalomyelitis with and without antibodies to the myelin oligodendrocyte glycoprotein. *J Neurol Neurosurg Psychiatry.* 2015 Mar;86(3):265-72. doi: 10.1136/jnnp-2014-308346. Epub 2014 Aug 13. PMID: 25121570.
- Cohen O, Steiner-Birmanns B, Biran I, Abramsky O, Honigman S, Steiner I. Recurrence of acute disseminated encephalomyelitis at the previously affected brain site. *Arch Neurol.* 2001 May;58(5):797-801. doi: 10.1001/archneur.58.5.797. PMID: 11346375.
- Garg RK. Acute disseminated encephalomyelitis. *Postgrad Med J.* 2003 Jan;79(927):11-7. doi: 10.1136/pmj.79.927.11. PMID: 12566545; PMCID: PMC1742586.
- Ogawa R, Nakashima I, Takahashi T, Kaneko K, Akaishi T, Takai Y, Sato DK, Nishiyama S, Misu T, Kuroda H, Aoki M, Fujihara K. MOG antibody-positive, benign, unilateral, cerebral cortical encephalitis with epilepsy. *Neurol Neuroimmunol Neuroinflamm.* 2017 Jan 16;4(2):e322. doi: 10.1212/NXI.0000000000000322. PMID: 28105459; PMCID: PMC5241006.
- Jindahra P, Plant T. Update on neuromyelitis optica: natural history and management. *Eye Brain.* 2012 Mar 26;4:27-41. doi: 10.2147/EB.S8392. PMID: 28539779; PMCID: PMC5436187.
- Krupp LB, Banwell B, Tenenbaum S; International Pediatric MS Study Group. Consensus definitions proposed for pediatric multiple sclerosis and related disorders. *Neurology.* 2007 Apr 17;68(16 Suppl 2):S7-12. doi: 10.1212/01.wnl.0000259422.44235.a8. PMID: 17438241.
- Young NP, Weinshenker BG, Lucchinetti CF. Acute disseminated encephalomyelitis: current understanding and controversies. *Semin Neurol.* 2008 Feb;28(1):84-94. doi: 10.1055/s-2007-1019130. PMID: 18256989.

**This series is brought to you by**



THE *Sumaira* FOUNDATION

**Special thanks to**

**Elias Sotirchos, MD**

Assistant Professor of Neurology at Johns Hopkins University  
Director of the Johns Hopkins Neuromyelitis Optica Clinic

NOTE: This briefing is for educational purposes and is not meant to replace medical advice